



Poruchy srdečního rytmu

Jan Sebroň

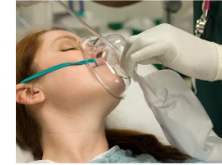jan.sebron@tul.cz

Poruchy srdečního rytmu

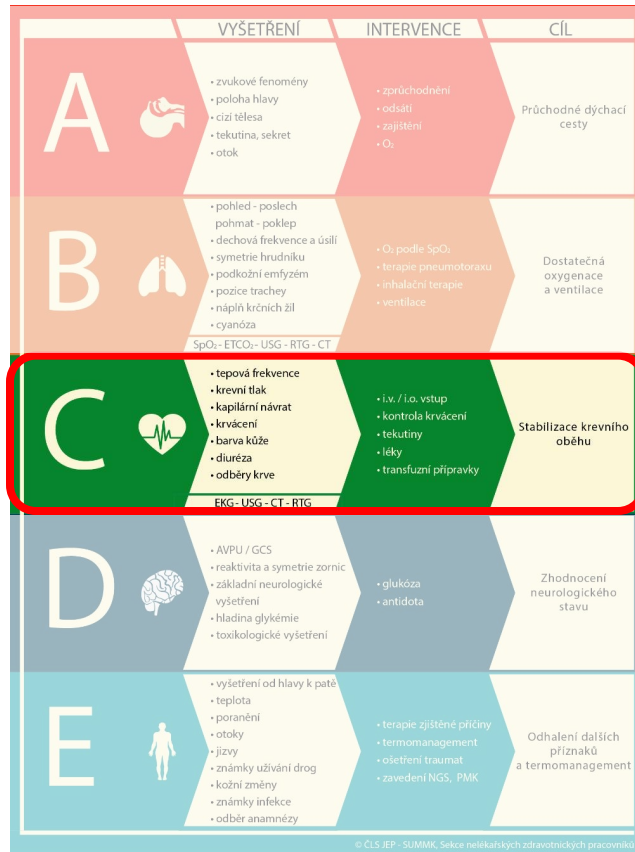O₂

i.v. vstup

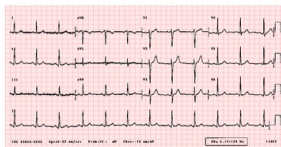
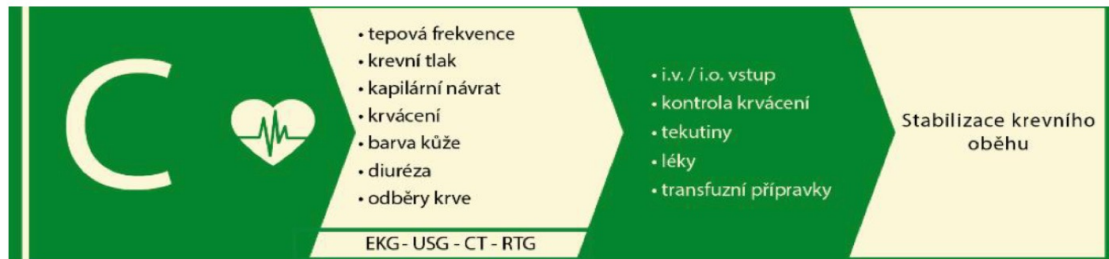	VYŠETŘENÍ	INTERVENCE	CÍL
A	<ul style="list-style-type: none"> • zvukové fenomény • poloha hlavy • cizí tělesa • tekutina, sekret • otok 	<ul style="list-style-type: none"> • zprůchodnění • odsátí • zajištění • O₂ 	Průchodné dýchací cesty
B	<ul style="list-style-type: none"> • pohled - poslech • pohmat - poklep • dechová frekvence a úsilí • symetrie hrudníku • podkožní emfyzém • pozice trachey • naplň krčních žil • cyanóza <p>SpO₂- ETCO₂- USG - RTG - CT</p>	<ul style="list-style-type: none"> • O₂ podle SpO₂ • terapie pneumotoraxu • inhalační terapie • ventilace 	Dostatečná oxygenace a ventilace
C	<ul style="list-style-type: none"> • tepová frekvence • krevní tlak • kapilární návrat • krvácení • barva kůže • diuréza • odběry krve <p>EKG- USG - CT - RTG</p>	<ul style="list-style-type: none"> • i.v. / i.o. vstup • kontrola krvácení • tekutiny • léky • transfuzní přípravky 	Stabilizace krevního oběhu
D	<ul style="list-style-type: none"> • AVPU / GCS • reaktivita a symetrie zornic • základní neurologické vyšetření • hladina glykémie • toxikologické vyšetření 	<ul style="list-style-type: none"> • glukóza • antidota 	Zhodnocení neurologického stavu
E	<ul style="list-style-type: none"> • vyšetření od hlavy k patě • teplota • poranění • otoky • jizvy • známky užívání drog • kožní změny • známky infekce • odběr anamnézy 	<ul style="list-style-type: none"> • terapie zjištěné příčiny • termomanagement • ošetření traumat • zavedení NGS, PMK 	Odhalení dalších příznaků a termomanagement



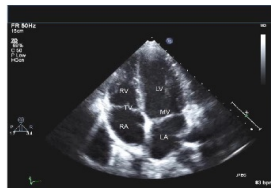
Poruchy srdečního rytmu



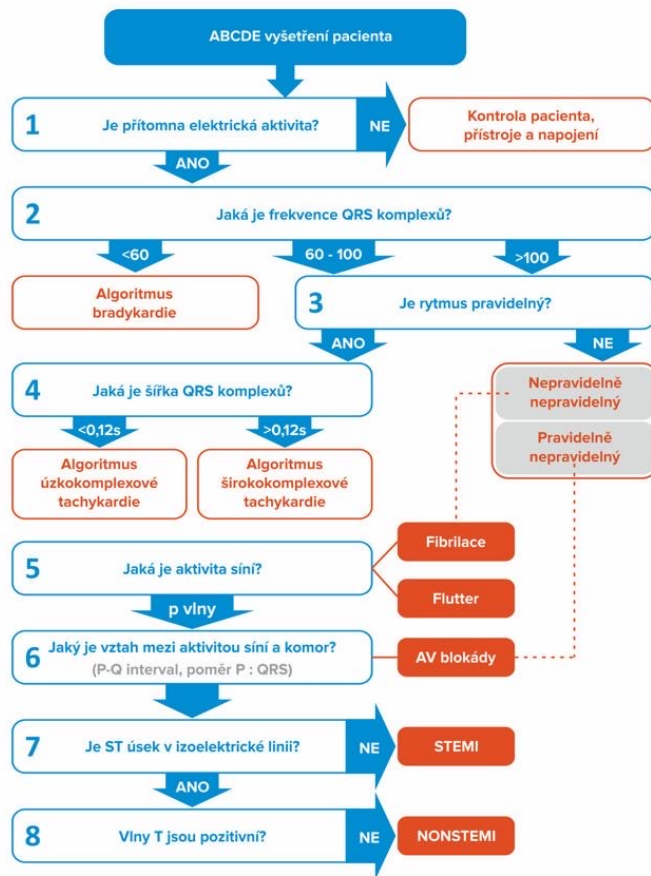
Poruchy srdečního rytmu



sTK > 100



Hodnocení EKG v 8 krocích



Poruchy srdečního rytmu



Nedělat nic /



Poruchy srdečního rytmu



Nedělat nic /

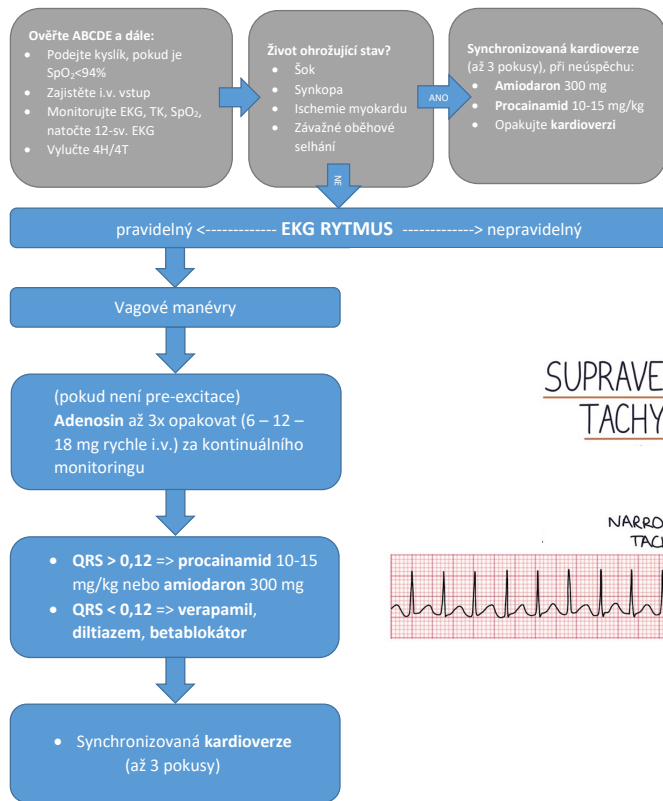


OMG+

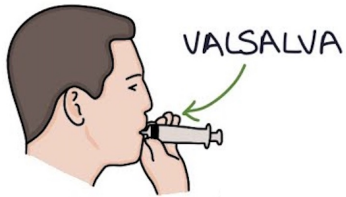
1. ŠOK
2. SYNKOPA
3. AKS / IM
4. SRDEČNÍ SELHÁNÍ

Tachykardie TF $>100/\text{min}$

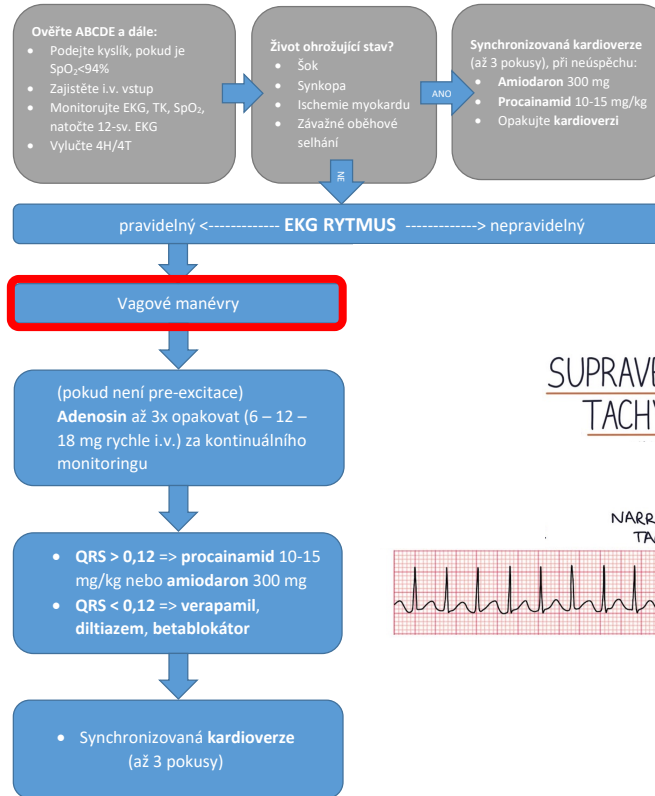
TACHYKARDIE



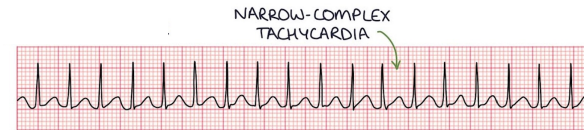
TACHYKARDIE



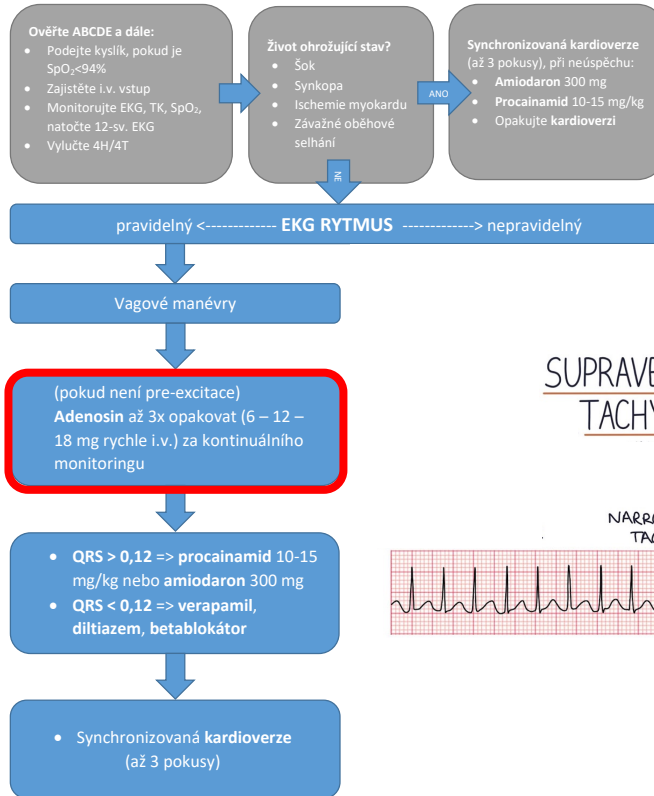
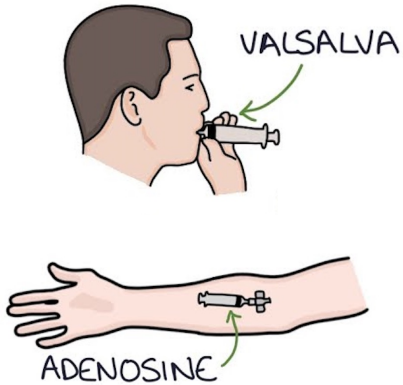
VALSALVA



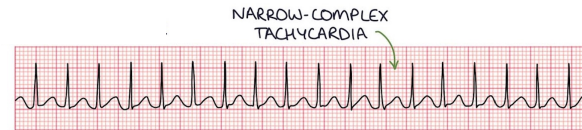
SUPRAVENTRICULAR TACHYCARDIA



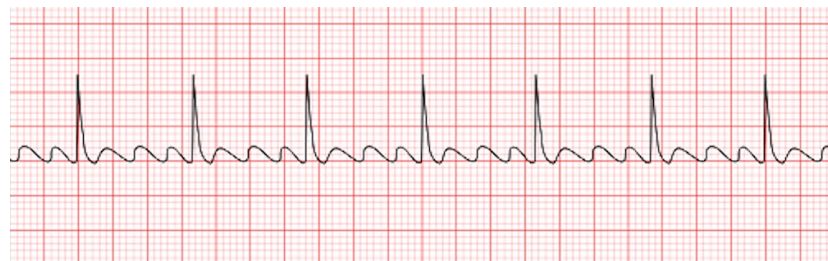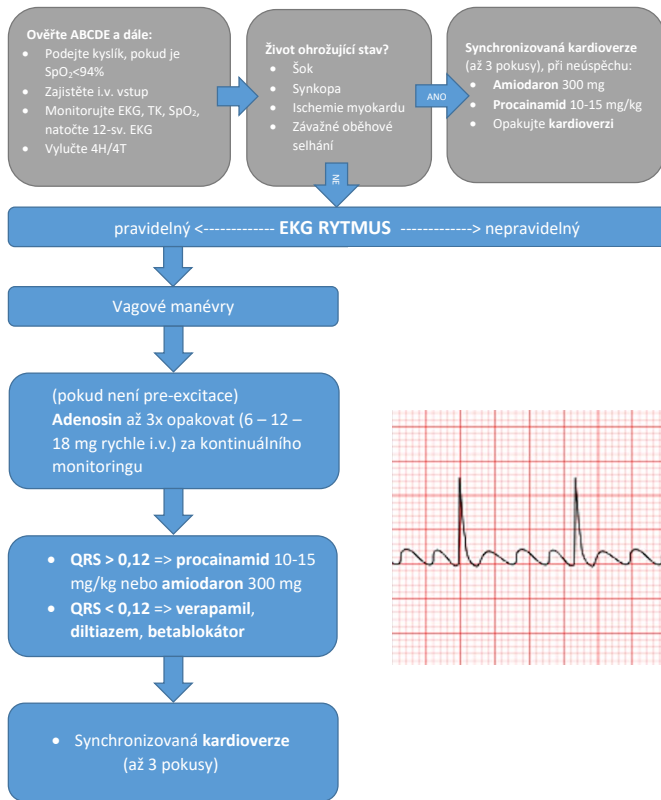
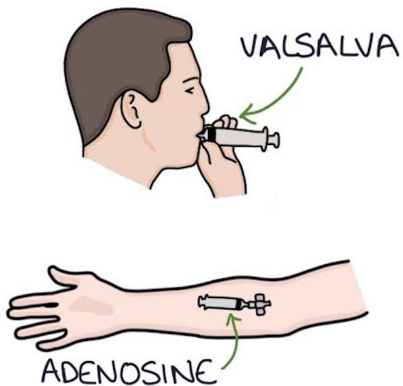
TACHYKARDIE



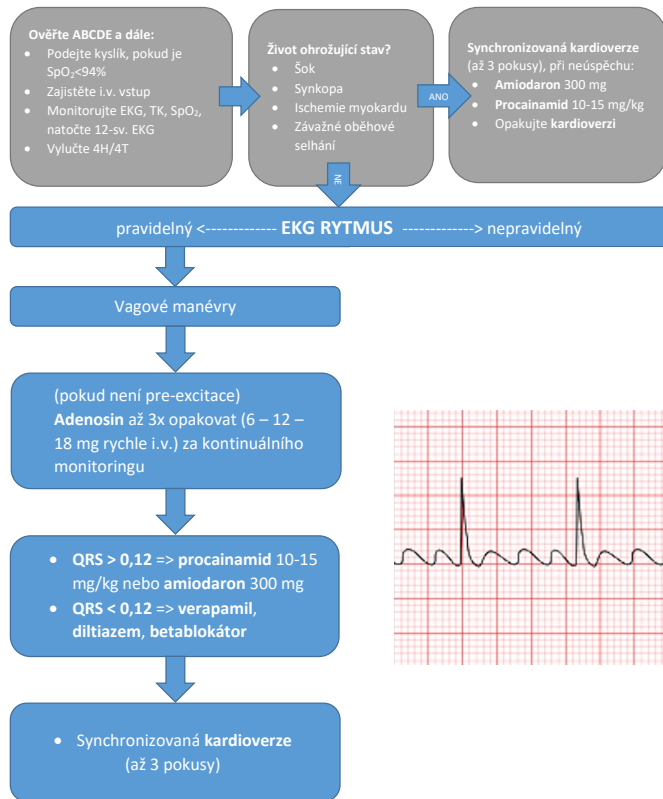
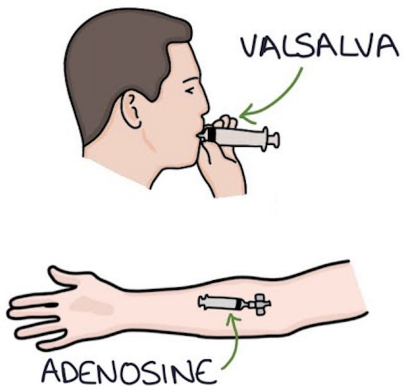
SUPRAVENTRICULAR TACHYCARDIA



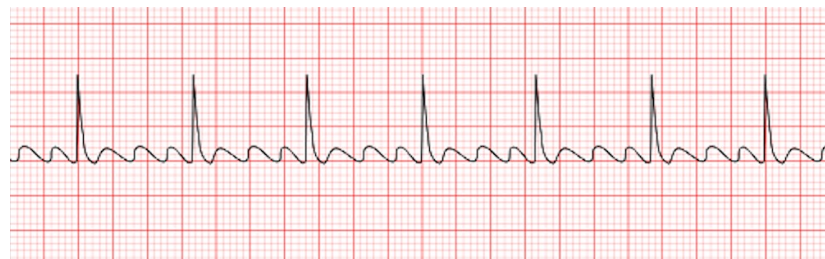TACHYKARDIE



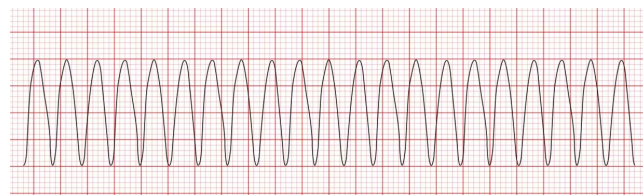
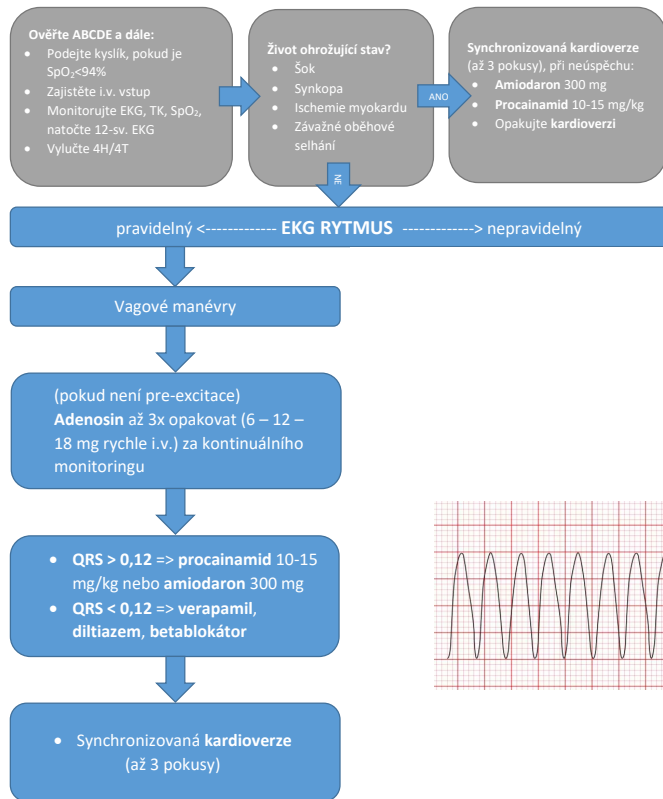
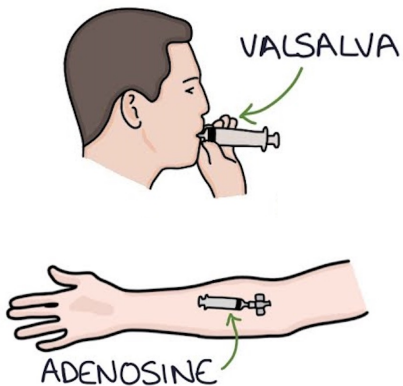
TACHYKARDIE



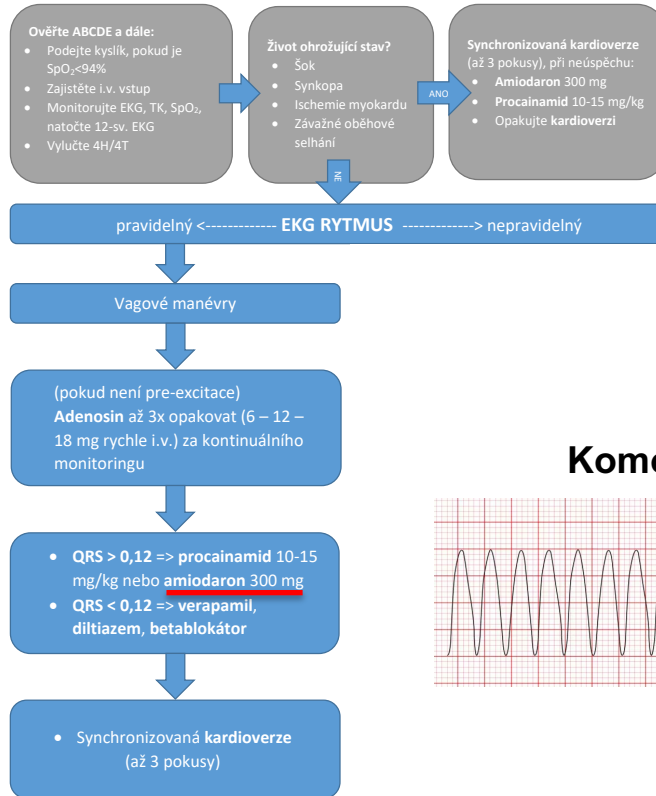
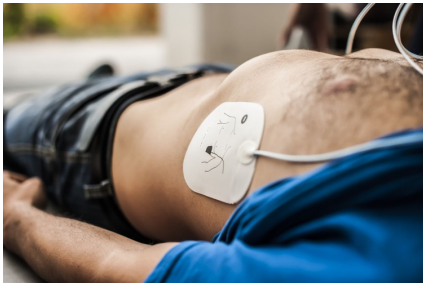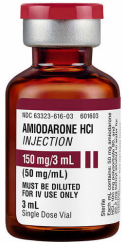Flutter síní



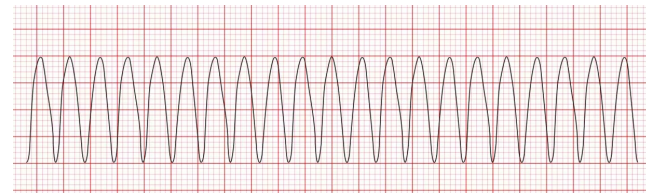
TACHYKARDIE



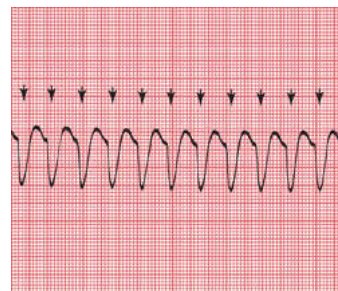
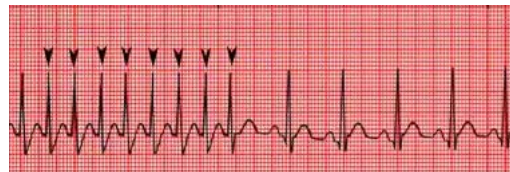
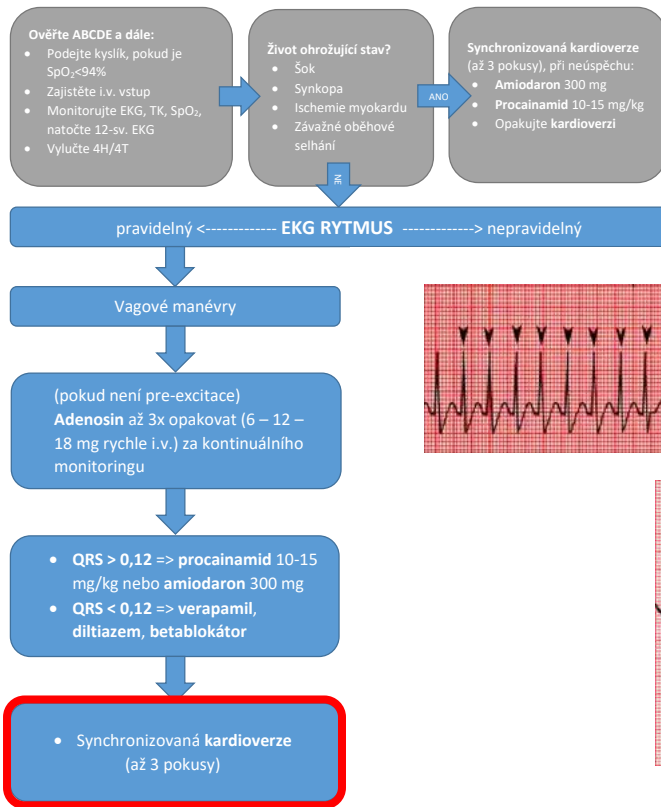
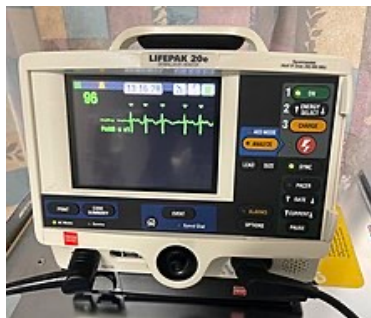TACHYKARDIE



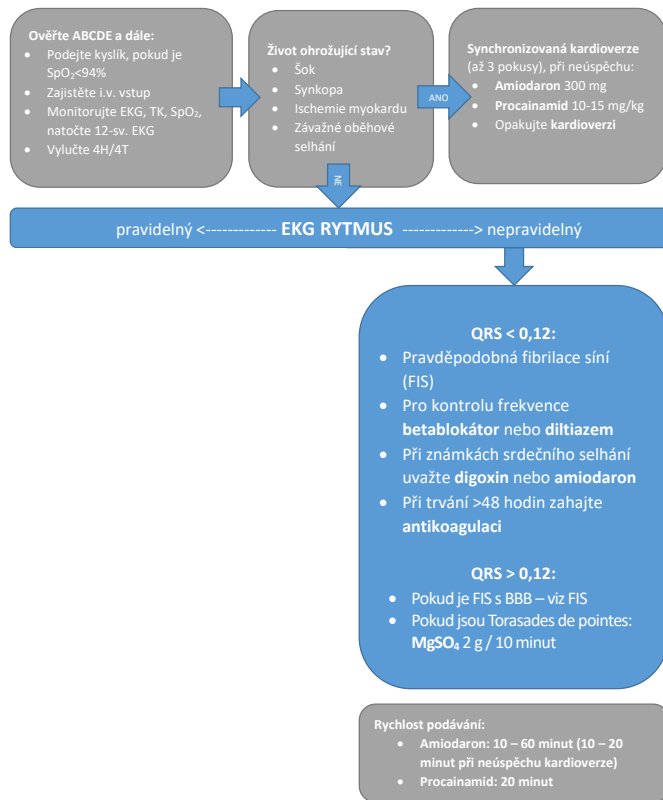
Komorová tachykardie



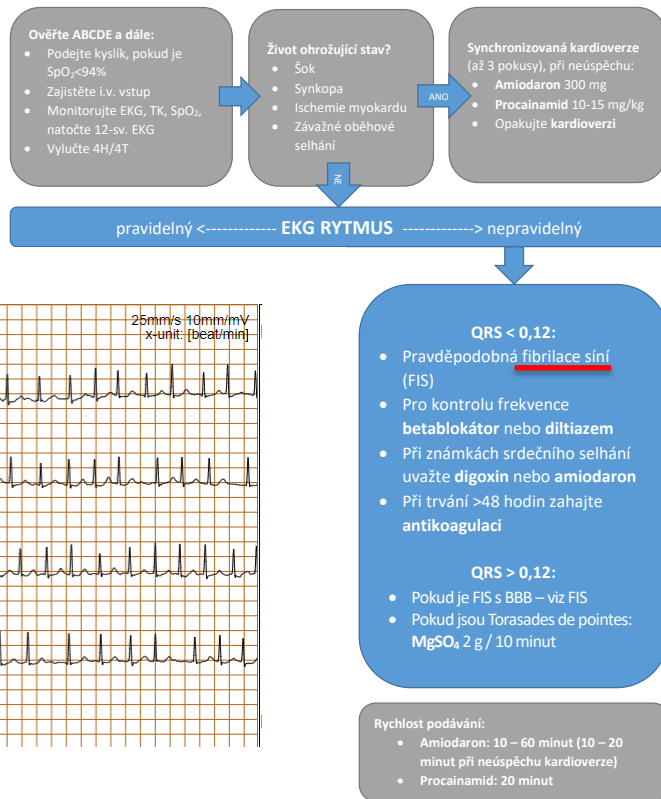
TACHYKARDIE



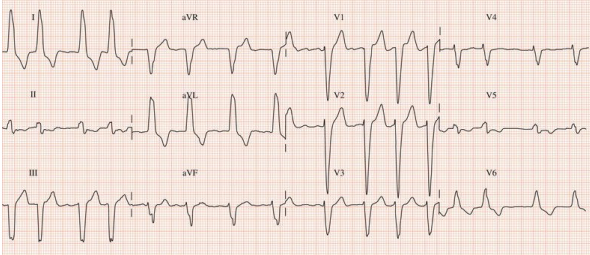
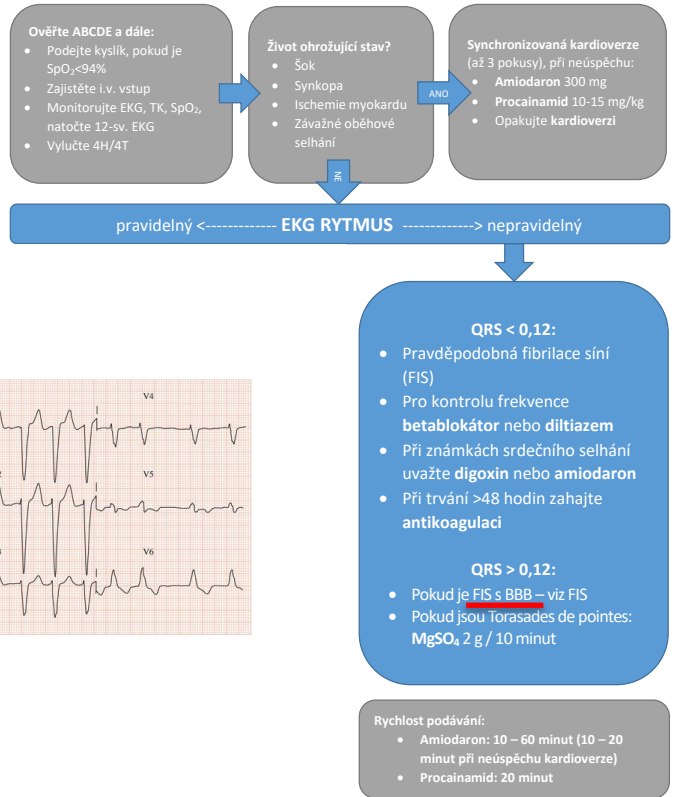
TACHYKARDIE



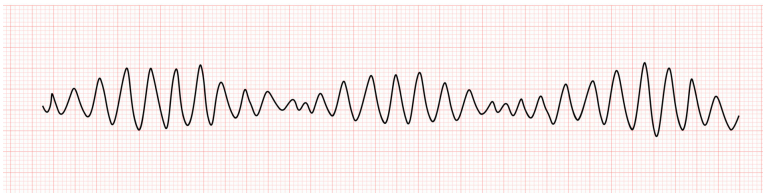
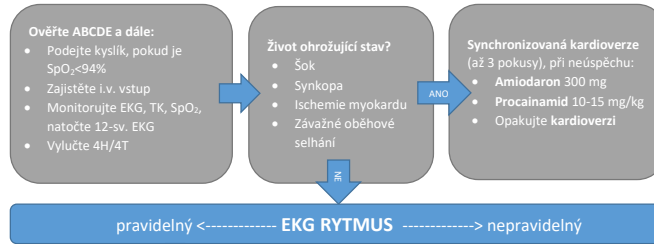
TACHYKARDIE



TACHYKARDIE



TACHYKARDIE



QRS < 0,12:

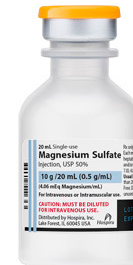- Pravděpodobná fibrilace síní (FIS)
- Pro kontrolu frekvence **betablokátor** nebo **diltiazem**
- Při známkách srdečního selhání uvažte **digoxin** nebo **amiodaron**
- Při trvání >48 hodin zahajte **antikoagulaci**

QRS > 0,12:

- Pokud je FIS s BBB – viz FIS
- Pokud jsou Torasades de pointes:
MgSO₄ 2 g / 10 minut

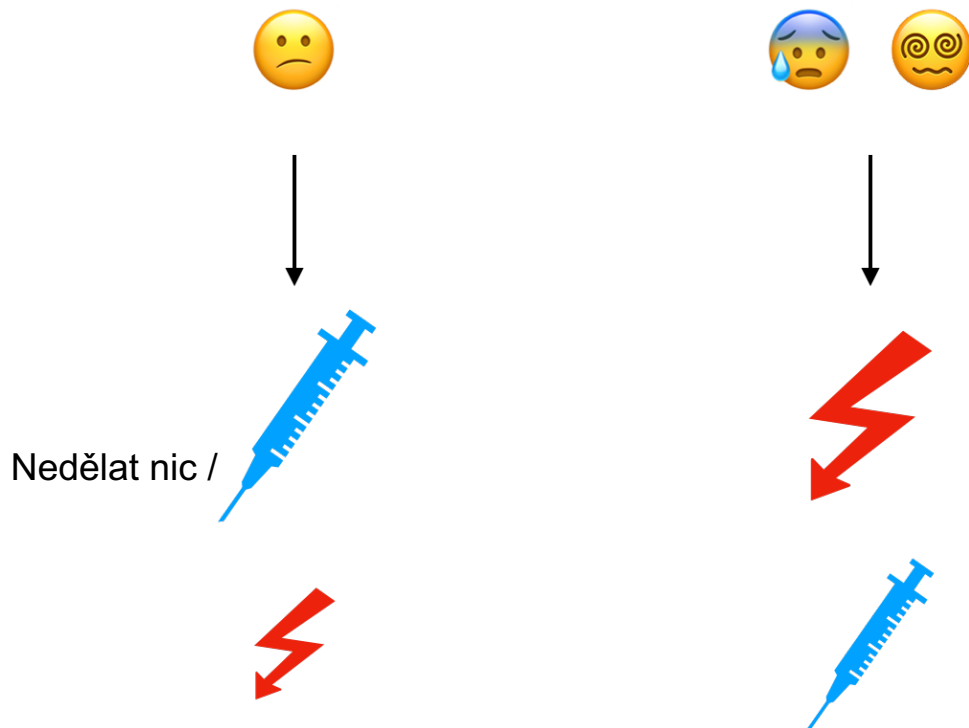
Rychlost podávání:

- Amiodaron: 10 – 60 minut (10 – 20 minut při neúspěchu kardioverze)
- Procainamid: 20 minut



Bradykardie TF <50/min

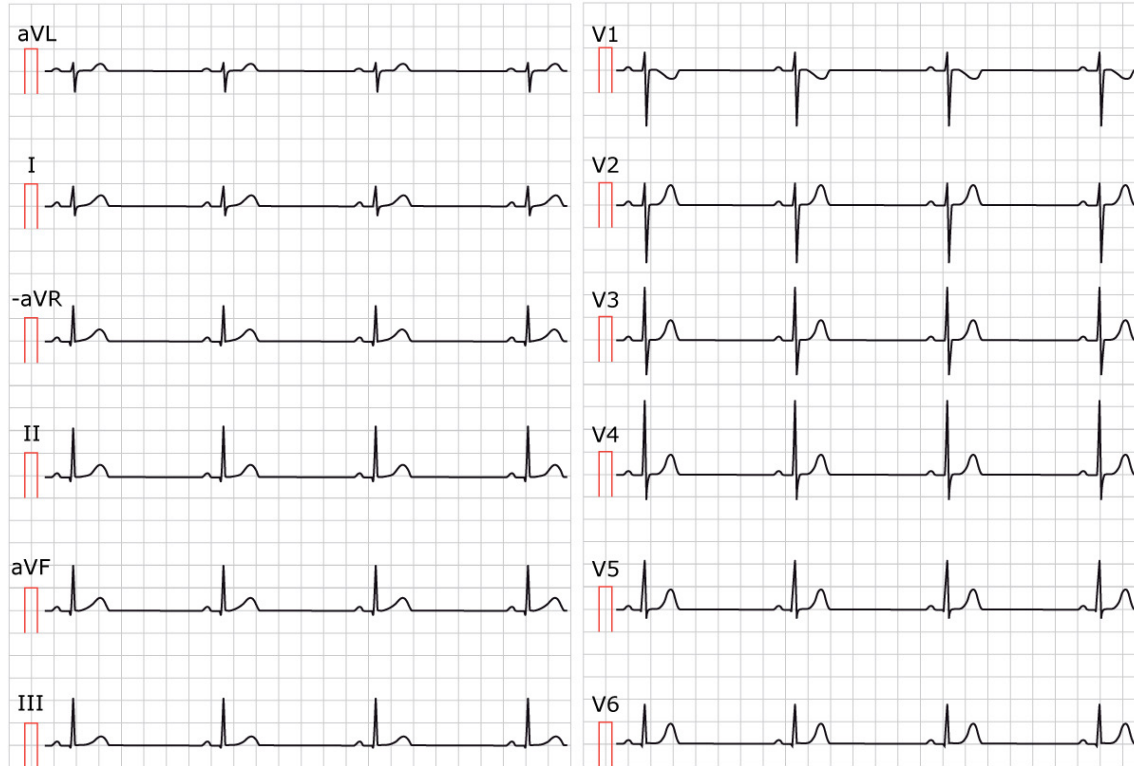
Poruchy srdečního rytmu



OMG+

1. ŠOK
2. SYNKOPA
3. AKS / IM
4. SRDEČNÍ SELHÁNÍ

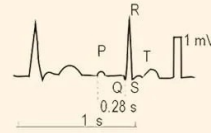
Bradykardie



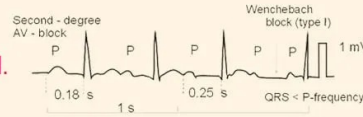
The Heart Block Poem

by the Princeton Surgical Group & [nurseslabs](#)

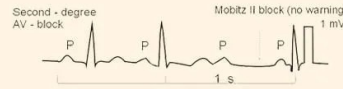If the **R** is far from **P**,
then you have a **FIRST DEGREE**.




Longer, longer, longer, drop!
Then you have a **WENKEBACH**.



If some **Ps** don't get through,
then you have **MOBITZ II**.



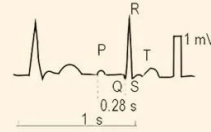
If **Ps** and **Qs** don't agree,
then you have a **THIRD DEGREE**.



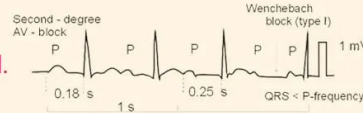The Heart Block Poem

by the Princeton Surgical Group & 

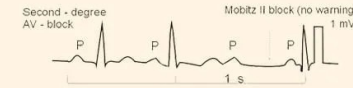If the **R** is far from **P**,
then you have a **FIRST DEGREE**.



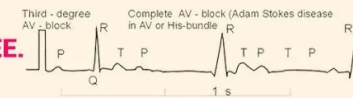
Longer, longer, longer, drop!
Then you have a **WENKEBACH**.



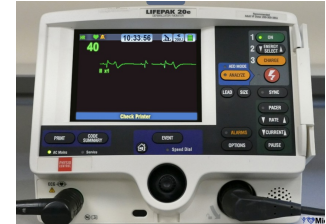If some **P**s don't get through,
then you have **MOBITZ II**.

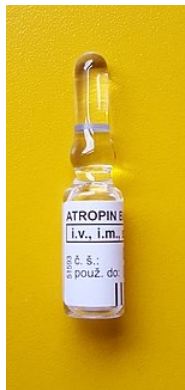


If **P**s and **Q**s don't agree,
then you have a **THIRD DEGREE**.

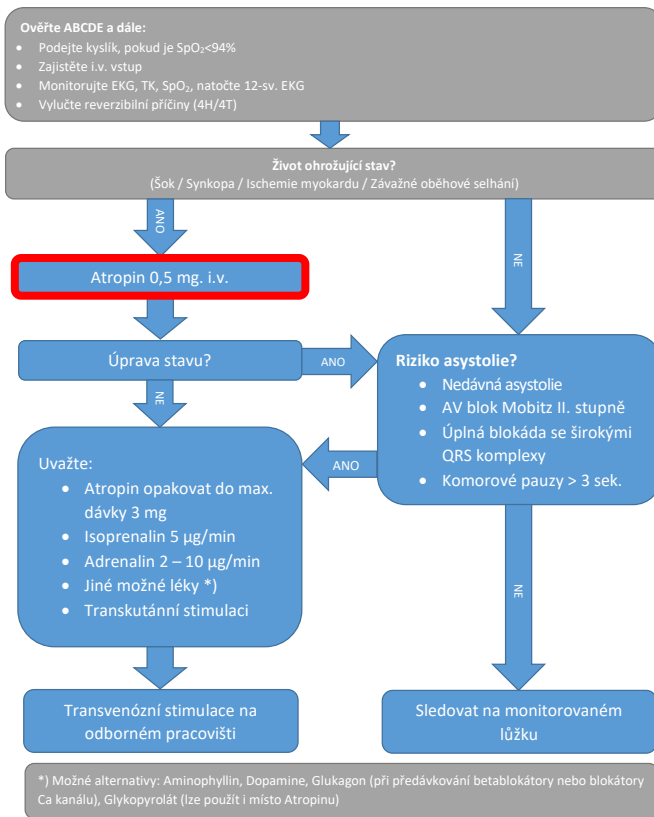


Riziko ASYSTOLIE!



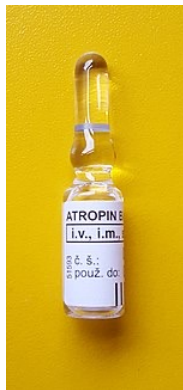

BRADYKARDIE

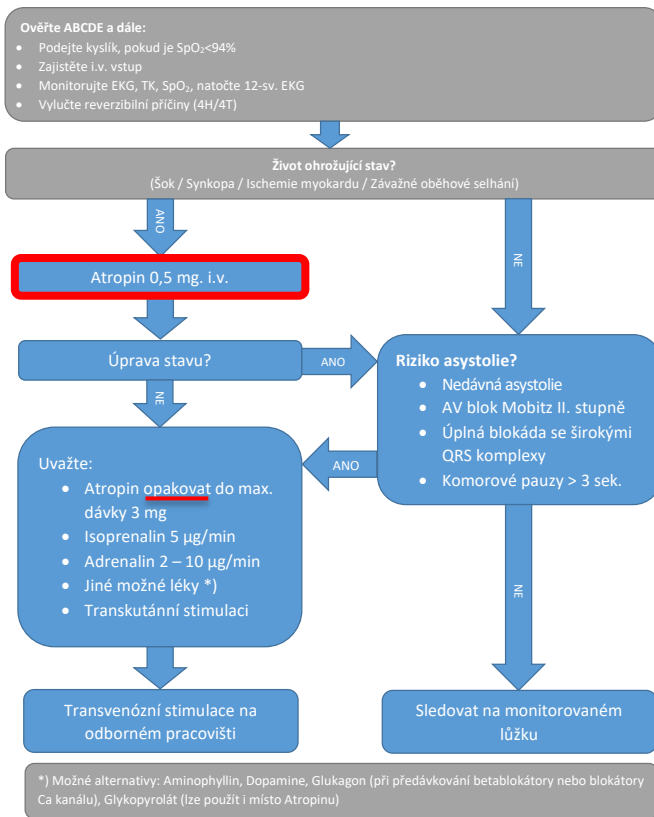


Zdroj: J. Soar, et al., European Resuscitation Council Guidelines 2021: Adult advanced life support, Resuscitation (2021),

<https://doi.org/10.1016/j.resuscitation.2021.02.010>
úprava © Ondřej Franěk, www.zachranaslužba.cz



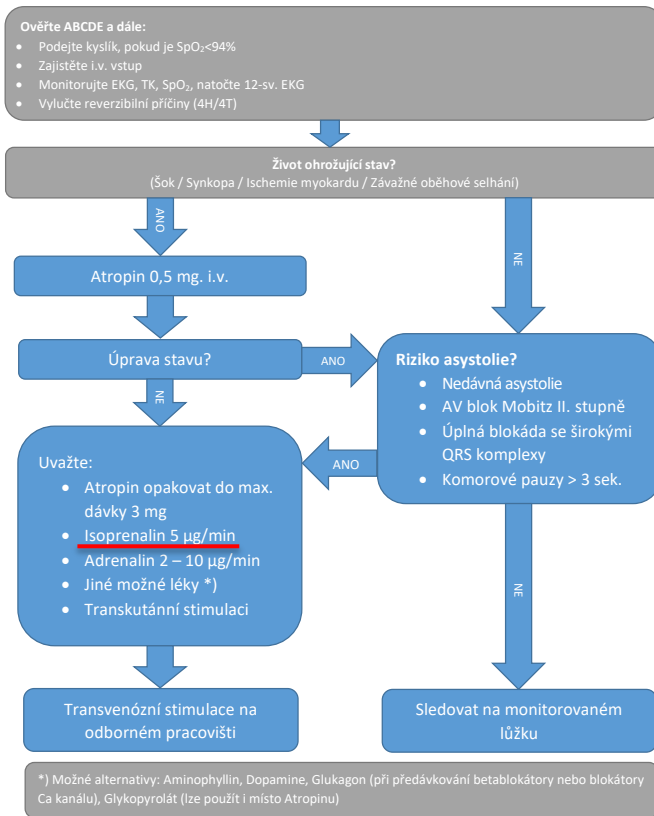
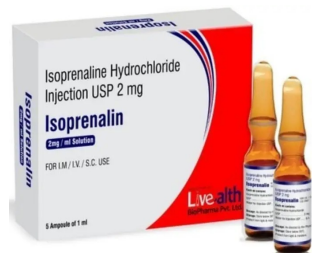BRADYKARDIE

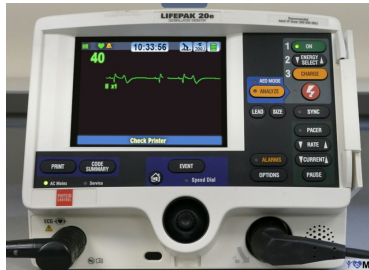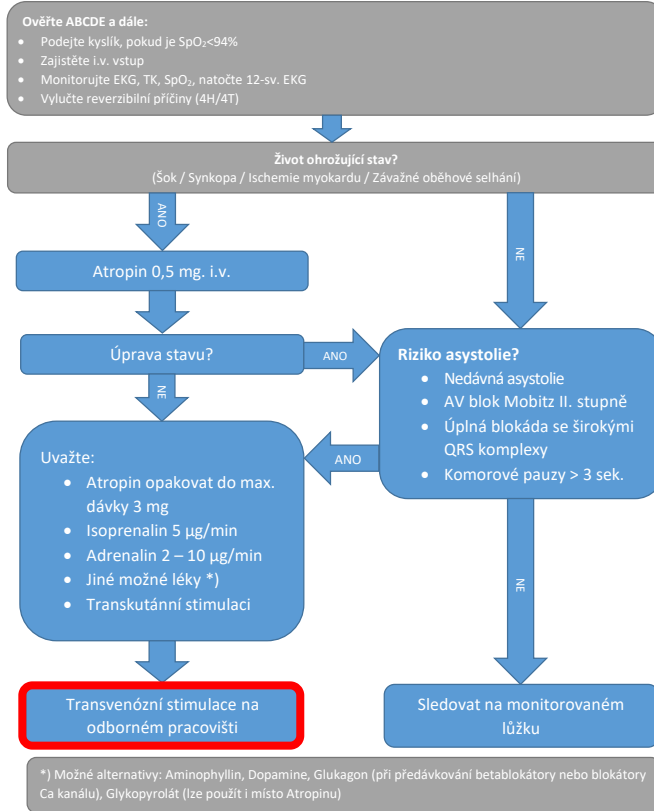


Zdroj: J. Soar, et al., European Resuscitation Council Guidelines 2021: Adult advanced life support, Resuscitation (2021),

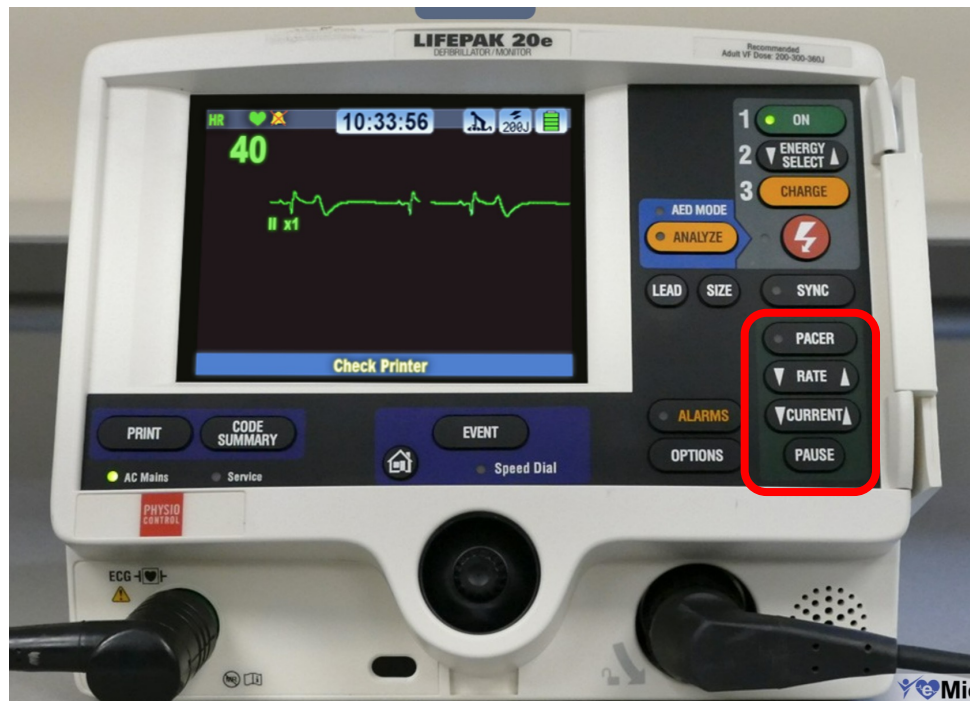<https://doi.org/10.1016/j.resuscitation.2021.02.010>,

úprava © Ondřej Franěk, www.zachrannaslužba.cz

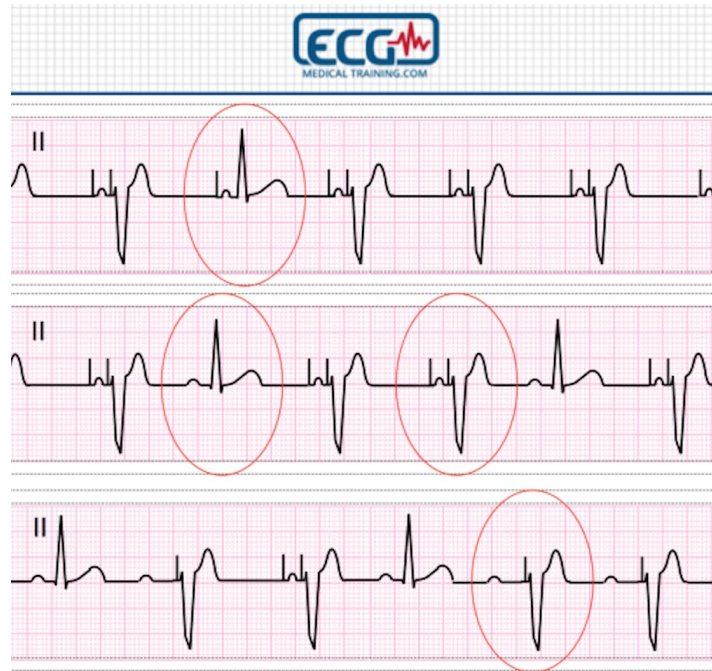
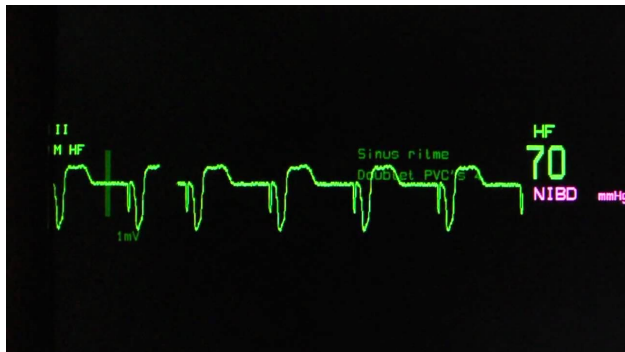




Bradykardie



Bradykardie





Děkuji za pozornost

Jan Sebroň

jan.sebron@tul.cz